



Italian Society  
of Periodontology  
and Implantology

## Radiographic outcomes of transcrestal sinus floor elevation performed with a minimally-invasive technique in smoker and non-smoker patients

Ricerca radiografica sui risultati di rialzo transcrestale del pavimento del seno mascellare eseguito con una tecnica mininvasiva in fumatori e non fumatori

Rizzi A.<sup>1</sup>, Franceschetti, G.<sup>1</sup>, Farina R.<sup>1</sup>, Stacchi C.<sup>2,3</sup>,  
Di Lenarda R.<sup>3</sup>, Di Raimondo R.<sup>4</sup>, Minenna L.<sup>1</sup>,  
Minenna P.<sup>5</sup>, Trombelli L.<sup>1</sup>

<sup>1</sup>Research Centre for the Study of Periodontal and Peri-Implant Diseases, University of Ferrara, Ferrara, Italy;

<sup>2</sup>Private practice, Gorizia, Italy;

<sup>3</sup>Department of Medical Sciences, University of Trieste, Italy;

<sup>4</sup> Private practice, Palermo, Italy;

<sup>5</sup> Private practice, Foggia, Italy

PROCEEDINGS BOOK RESEARCH SESSION "H.M. GOLDMAN PRIZE" 2013  
ATTI DELLA SESSIONE DI RICERCA "PREMIO H.M. GOLDMAN" 2013

### Summary

**Objectives:** to evaluate the association between smoking status and the outcomes of transcrestal sinus floor elevation (tSFE) performed with a minimally invasive technique (*Smart Lift*). **Methods:** forty-five implants were placed in 25 non-smoker (NS) and 20 smoker (S) patients in conjunction with the tSFE procedure. In all cases, an additional graft, chosen among different hydroxyapatite-based or  $\beta$ tricalcium phosphate-based biomaterials, was pushed into the sinus by gradual increments. Immediately after surgery, residual bone height, implant penetration into the sinus, extent of sinus lift (SL) and the height of the graft apical to the implant apex (aGH) were assessed on standardized periapical radiographs. At 6 months after surgery, SL and aGH were re-assessed. **Results:** (i) the *Smart Lift* procedure resulted in substantial 6-month SL and aGH in both treatment groups; (ii) smoking status did not significantly affect the 6-month radiographic outcomes; (iii) a similarly low incidence of intra- and postoperative complications was observed in NS and S patients. **Conclusions:** smoking has a limited impact on the outcomes of tSFE performed with the *Smart Lift* technique.

### Riassunto

**Obiettivi:** valutare l'associazione tra lo stato di fumatore e i risultati dell'intervento di rialzo transcrestale del pavimento del seno mascellare (tSFE) eseguito con una tecnica mininvasiva (*Smart Lift*). **Metodi:** quarantacinque impianti furono inseriti in 25 pazienti non-fumatori (NS) e 20 fumatori (S) in combinazione con l'intervento di tSFE. In tutti i casi un innesto addizionale, scelto tra differenti tipi di biomateriali a base di idrossiapatite o di beta-fosfato tricalcico, fu inserito nel seno mascellare con incrementi gradualmente. Immediatamente dopo l'intervento chirurgico furono accertati mediante radiografie periapicali standardizzate l'altezza dell'osso residuo, la dimensione della penetrazione dell'impianto nel seno, l'estensione del rialzo di seno (SL), e l'altezza del materiale di innesto apicalmente all'apice implantare (aGH). Dopo 6 mesi dall'intervento SL e aGH furono nuovamente registrate. **Risultati:** (i) il procedimento *Smart Lift* esitò in risultati sostanzialmente simili di SL e aGH a 6 mesi in entrambi i gruppi trattati; (ii)



lo stato di fumatore non influenzò in maniera significativa gli aspetti radiografici a 6 mesi; (iii) sia nei pazienti NS che in quelli S si verificò la stessa bassa incidenza di complicanze post-operatorie. Conclusioni: il fumo ha un impatto limitato sui risultati degli interventi di tSFE eseguiti con la tecnica *Smart Lift*.

## Introduction

The loss of maxillary posterior teeth may be associated with a reduction of the vertical dimension of the residual ridge partly resulting from the pneumatization of the maxillary sinus (Farina et al. 2011). In some instance, the insertion of implants of desired length in the edentulous posterior maxilla may therefore be not compatible with residual ridge height (Eufinger et al. 1997, 1999, Pramstraller et al. 2011). Transcrestal sinus floor elevation (tSFE) is a surgical procedure to vertically enhance the available bone in the edentulous posterior maxilla through an access to the sinus floor created into the bone crest. According to a recent systematic review, tSFE is highly cost-effective when performed at sites with a height of the residual ridge above 5 mm (Listl & Faggion 2010).

Smoking may negatively affect the healing capacity of injured tissues in several organ systems (Mosely et al. 1978). With regard to bone reconstructive procedures, smokers have been shown to respond less favorably to surgical procedures for ridge augmentation (Jones & Triplett 1992, Lindfors et al. 2010). Lower reconstructive outcomes and higher risk for infective complications following sinus lift with a lateral approach were reported for smokers compared to non-smokers (Barone et al. 2006, Anduze-Acher et al. 2012). Also, implants placed at sites undergone augmentation procedures including sinus elevation are at higher risk for failure in smokers than non-smokers (Geurs et al. 2001, Strietzel et al. 2007, Huynh-Ba et al. 2008, Lin et al. 2012). To date, no specifically designed studies have addressed the effect of smoking on the outcomes of tSFE procedures.

Recently, we proposed a minimally-invasive procedure for tSFE, namely the *Smart Lift* technique, which is characterized by a transcrestal access to the sinus cavity by means of specially-designed drills and osteotomes (Trombelli et al. 2008, Trombelli et al. 2010a,b). Previous studies showed that the *Smart Lift* technique results in a predictable, apical displacement of the sinus floor (Trombelli et al. 2010a, 2012) along with a limited post-operative morbidity (Trombelli et al. 2010a). The present study was performed to evaluate the association between smoking status and the radiographic outcomes of tSFE performed according to the *Smart Lift* technique.

## Materials and Methods

### Experimental design

The study was designed as a prospective cohort study. All the clinical procedures were performed in full accordance with the Declaration of Helsinki and the Good Clinical Practice Guidelines (GCPs). Each patient provided a written informed consent before participation. The present manuscript was prepared in full accordance with STROBE guidelines for reporting cohort studies (<http://www.strobe-statement.org>).

### Patient selection

Patients were consecutively recruited and treated at 1 University center and 3 private dental offices from 2008 to 2010.

Inclusion criteria for patient eligibility were: (i) age  $\geq$  18 years; (ii) systemic and local conditions compatible with implant placement and sinus floor elevation procedures; (iii) placement of an implant  $\geq$  8 mm long concomitant with tSFE; (iv) non-smoker (NS) (i.e., patient who had never smoked) or current cigarette smoker (S) (i.e., patient who smoked at least 5 cigarettes per day (cig/day) at the screening visit); (v) patient willing and fully capable to comply with the study protocol. For S patients, the daily cigarette consumption as well as the number of years of



smoking habit were recorded.

Site-specific inclusion criteria were: (i) at least 6 months elapsed from tooth loss; (ii) residual bone height (as radiographically assessed pre-surgery and clinically confirmed with the *Probe Osteotome* during tSFE procedure)  $\geq 4$  mm and  $\leq 8$  mm; (iii) absence of endodontic lesions at teeth adjacent to the implant site.

### Surgical procedure

Before sinus lift procedure, all oral diseases, including periodontal disease, were thoroughly treated. The residual bone height at the site where the implant had to be inserted was first measured on periapical radiograph or CT scan. Two grams of amoxicillin (Zimox 1 g; Pfizer Italia S.r.l., Borgo San Michele, Italy) were administered to each patient 1 hour prior to the initiation of the surgical procedure.

The *Smart Lift* procedure represents a modification of the technique proposed by Fugazzotto (Fugazzotto & De Paoli 2002). The major novelty of the *Smart Lift* resides in the fact that all manual and rotating instruments are used with adjustable stop devices that restrict the working action of burs and osteotomes to the vertical amount of residual bone, thereby preventing the accidental penetration of instruments into the sinus cavity.

Moreover, with the *Smart Lift* technique, the vertical augmentation of the implant site is provided by the condensed trephined bone core that is displaced into the sinus, thus elevating the Schneiderian membrane and creating a space for blood clot formation.

The preparation of the implant site is performed according to a standardized sequence of instruments which was extensively described in previous studies (Trombelli et al. 2010a,b, 2012, Figure 1).

Fig 1. Smart lift procedure: sequence of rotating and manual instruments

**a.** The *Locator Drill* is used to perforate the cortical bone at the site where the implant has to be placed. **b.** The *Probe Drill* is used to define the orientation of the implant, with an adjustable stop device set at least 1 mm shorter than the radiographic working length. **c.** The *Probe Osteotome* is gently forced in an apical direction until the cortical bone resistance of the sinus floor is met, thus providing the “surgical working length” (sWL). The working action of all instruments included in the succeeding surgical steps is set at the sWL by using the proper adjustable stop device. **d.** A radiographic pin may be used to check the orientation of the prepared site by means of a periapical radiograph. **e.** The “*Guide Drill*” is used to create a crestal countersink. **f.** The *Smart Lift Drill* produces a bone core up to the sinus floor. **g,h.** The bone core is condensed and malleted to fracture the sinus floor by means of the *Smart Lift Elevator*. A graft biomaterial may be placed into the sinus cavity by gradual increments with the *Smart Lift Elevator*.

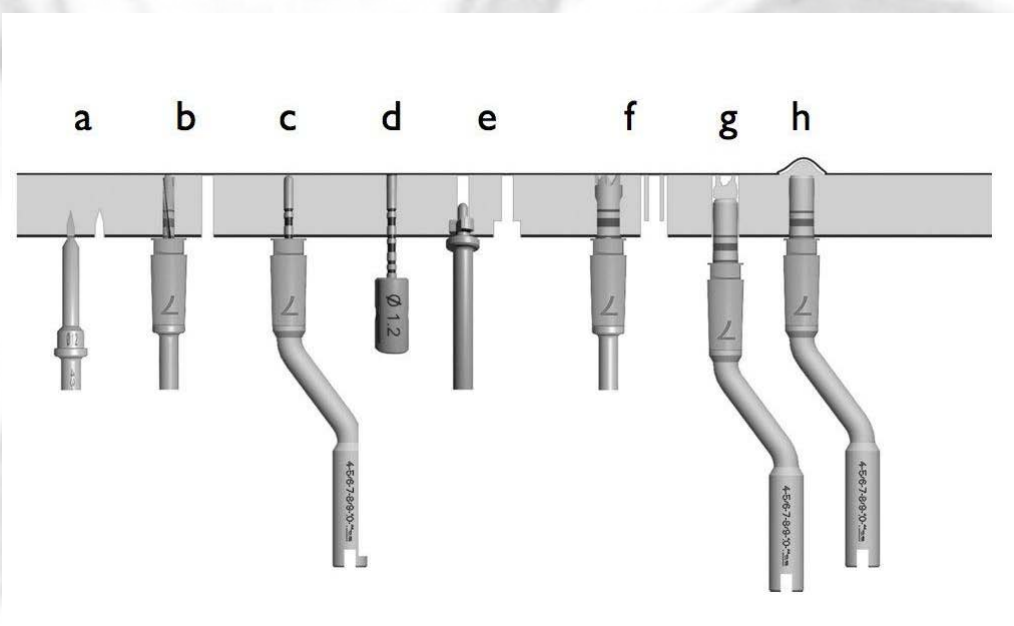


Figure reprinted from: Trombelli, L., Franceschetti, G., Rizzi, A., Minenna, P., Minenna, L. & Farina, R. (2012) Minimally invasive transcrestal sinus floor elevation with graft biomaterials. A randomized clinical trial. *Clinical Oral Implants Research* **23**:424–432.



In all cases, an additional graft, chosen among different hydroxyapatite-based (Bio-Oss® spongiosa granules 0.25-1.0 mm; Geistlich Pharma, AG, Wolhusen, Switzerland; Biostite®; GABA Vebas, S. Giuliano Milanese, Milan, Italy; Gen-Os®; Osteobiol Tecross Dental, Pianezza, Torino, Italy) or  $\beta$ -tricalcium phosphate-based (Ceros®, granules 0.5-0.7 mm; Thommen Medical, Waldenburg, Switzerland) biomaterials, was pushed into the sinus by gradual increments using the *Smart Lift Elevator*. The choice and amount of the graft biomaterial was left at the operator's discretion. The implant was inserted with either submerged or transmucosal healing protocol.

Patients were prescribed a non-steroidal anti-inflammatory agent as needed, and 0.12% chlorhexidine mouthrinse, 10 ml t.i.d. for 3 weeks. The choice of a post-surgery antibiotic treatment was left to the discretion of the operator. Sutures were removed 7 days after surgery.

### **Experimental parameters**

#### *Surgical and post-surgical complications*

The incidence of membrane perforation was evaluated by the Valsalva maneuver immediately after the fracture of the sinus floor by means of the *Smart Lift Elevator* and at the completion of the grafting procedure.

Other surgical or post-surgical complications associated with the sinus lift procedure, including Benign Paroxysmal Positional Vertigo (BPPV), post-operative infection, post-operative haemorrhage, nasal bleeding, blocked nose, haematomas, either assessed by the operator or reported by the patient, were also recorded.

#### *Radiographic measurements*

Radiographs were obtained immediately after surgery and at 6 months with a paralleling technique using a Rinn film holder with a rigid film-object X-ray source, then scanned and digitized. Using an image-processing software, digitized images were stored at a resolution of 600 dpi. On radiographs taken immediately after surgery, the following radiographic measurements were performed using a digital caliper:

- radiographic implant length (rIL): distance (in mm) between the implant shoulder and the implant apex as assessed at the mid portion of the implant;
- residual bone height at the mesial (mRBH) and distal (dRBH) aspects of the implant: distance (in mm) between the mesial and distal aspect of the implant shoulder, respectively, and the sinus floor;
- height of the graft apically (aGH): distance (in mm) occupied by a radiopaque area between the implant apex and the sinus floor as assessed at the mid portion of the implant.

To account for radiographic distortion, radiographic measurements (i.e., mRBH, dRBH and aGH) on each radiograph were adjusted for a coefficient derived from the ratio: true length of the implant/rIL. aGH was reassessed at 6 months after adjustment for 6-month rIL.

For each patient, the following derived radiographic parameters were obtained:

- residual bone height (RBH): calculated as the mean value of mRBH and dRBH;
- implant penetration (IP): calculated as the difference between rIL and RBH;
- extent of the sinus lift (SL): calculated as the sum of IP and aGH.

All measurements were performed by a single trained examiner (G.F.) who had previously undergone a calibration session for aGH assessment on a sample of 15 patients not included in the study (k-score for intraexaminer agreement: 0.981) and had participated as clinical examiner in a previous clinical trial using the same radiographic measurements (Trombelli et al. 2012).

### **Statistical Analysis**

Data were entered in a unique database file (STATISTICA® software version 7.1; StatSoft, Italia s.r.l., Vigonza, Italy) and expressed as median (interquartile range). The statistical analysis was conducted on the intention-to-treat (ITT) study population. The patient was regarded as the



statistical unit. 6-month aGH and SL were regarded as the primary and secondary outcome variable, respectively.

Smoking exposure (pack\*years) was calculated as [(number of cigarettes/day / 20) \* number of years of smoking]. S patients were categorized according to either the daily cigarette consumption (low: < 15 cigarettes/day; moderate: ≥ 15 and < 20 cigarettes/day; high: ≥ 20 cigarettes/day) or their smoking exposure (low: ≤ 15 pack \* years; moderate: 16 ÷ 29 pack \* years; high: ≥ 30 pack \* years).

NS and S groups, S patients with different daily cigarette consumption and S patients with different smoking exposure were compared for outcome variables as well as for demographic characteristics (age, gender) and aspects related to the surgical procedure (RBH, implant length and width, IP). Within-group comparisons (presurgery vs. 6 months) were performed with Wilcoxon test. Inter-group comparisons were performed with Fisher's exact test,  $\chi^2$  test, Mann-Whitney U test and Kruskal-Wallis ANOVA.

The level of statistical significance was fixed at 0.05. When testing for multiple comparisons, the Bonferroni correction was applied.

Assuming a standard deviation in aGH of 1.0 mm and an expected inter-group difference in aGH of 1.0 mm, a sample of 40 patients (20 patients per each category according to smoking status) had a power of 89% in detecting a significant inter-group difference (at  $p = 0.05$ ) with a two-sided test.

## Results

### *Study population*

The ITT population consisted of 45 patients (age: 53.0 years, IR: 47-58, range: 27-70; 28 females) undergone 45 tSFE. One implant in a S patient failed to osseointegrate before the 6-month visit. For this patient, radiographic measurements were not performed at 6 months.

NS and S patients were 25 and 20, respectively. None of the patients in the S group referred a variation in the smoking habit between baseline and the 6-month visit. The description of demographic characteristics and aspects related to the surgical procedure in NS and S groups is reported in Table 1. tSFE was performed with additional use of Bio-Oss® spongiosa granules in 14 NS and 8 S patients, Biostite® in 7 NS and 8 S patients, Gen-Os® in 4 NS and 3 S patients, and Ceros® in 1 S patient. No significant difference in patient distribution according to the type of graft biomaterial was observed between NS and S groups. Patient distribution according to implant system in NS and S groups is shown in Table 2.

In S group, daily cigarette consumption was 15.0 cig/day (IR: 14.5-20.0, range: 6-40). Daily cigarette consumption was low (10 cig/day, IR: 10-12, range: 6-13) in 5 patients, moderate (15 cig/day, IR: 15-15, range: 15-18) in 8 patients, and high (20 cig/day, IR: 20-35, range: 20-40) in 7 patients ( $p < 0.001$ ).

Smoking exposure was 18.4 pack\*years (IR: 13.3-26.3, range: 3-40). Smoking exposure was low (10.2 pack\*years, IR: 7.5-13.9, range: 3.0-15.0) in 8 patients, moderate (22.5 pack\*years, IR: 18.4-23.8, range: 17.5-25.0) in 7 patients, and high (30 pack\*years, IR: 30.0-40.0, range: 30.0-40.0) in 5 patients ( $p < 0.001$ ).

No differences in demographic characteristics and aspects related to the surgical procedure were found between S patients with either different daily cigarette consumption or different smoking exposure.

### *Incidence of surgical and post-surgical complications in patients with different smoking status*

Membrane perforation was diagnosed after the fracture of the sinus floor in 2 NS patients. In these cases, the perforation was managed by inserting a surgical haemostatic dressing (Gingostat®; GABA Vebas, S. Giuliano Milanese, Milan, Italy) through the crestal access, and then the site was grafted. One case of membrane perforation was revealed after the completion of the placement

of the graft biomaterial in a S patient. In all cases of membrane perforation, the implant was inserted and the case included for analysis.

No statistically significant difference in the incidence of membrane perforation was observed between NS and S groups.

Over the course of the first postoperative week, 1 S patient referred paresthesia in the sub-orbital area and 1 NS patient referred tinnitus. Both complications were homolateral to the tSFE, and spontaneously subsided within the first week following surgery.

#### *Radiographic measurements*

aGH and SL values in NS and S groups are reported in Table 3. No difference in either aGH or SL was observed between groups immediately after surgery. Limited, non-significant modifications in aGH and SL were observed at 6 months compared to post-surgery in each group. At 6 months, no significant difference in aGH and SL was observed between groups.

When S patients with either different daily cigarette consumption or different smoking exposure were compared for radiographic measurements at post-surgery and 6 months, no significant differences were observed (data not shown).

Table 1. Characterization of patients with different smoking status. Data are expressed as median, IR, and range.

	<b>non smokers (NS)</b>	<b>smokers (S)</b>	<b>p (mann-Whitney)</b>	<b>p (X<sup>2</sup> or Fisher's exact test)</b>
<b>n° of patients</b>	25	20		
<b>Daily cigarette consumption (cigarettes/day)</b>	0	15 (IR: 14.5-20.0, range: 6-40)		
<b>smoking exposure (pack*years)</b>	0	18.4 (IR: 13.3-26.3, range: 3-40)		
<b>age (years)</b>	54.0 (IR: 49.0-60.0, range: 37-70)	52.5 (IR: 43.8-57.0, range: 27-64)	0.148	
<b>gender (males/females)</b>	9/16	8/12		0.227
<b>RBH (mm)</b>	5.0 (IR: 4.2-6.1, range: 3.3-7.6)	5.3 (IR: 4.7-5.8, range: 3.7-7.3)	0.676	
<b>implant length (mm)</b>	9.5 (IR: 8.5-10.0, range: 8.0-11.5)	9.5 (IR: 9.5-10.3, range: 8.0-11.0)	0.408	
<b>implant diameter (mm)</b>	4.0 (IR: 4.0-4.1, range: 3.3-5.0)	4.0 (IR: 4.0-4.5, range: 3.3-5.0)	0.359	
<b>IP (mm)</b>	4.1 (IR: 3.7-5.3, range: 2.2-6.3)	4.1 (IR: 3.7-4.9, range: 3.1-6.0)	0.865	



Table 2. Distribution of NS and S patients according to the implant system.

Implant system	non-smokers (NS, n=25)	smokers (S, n=20)
	n° patients	n° patients
SPI Element®	16	14
Certain® or Prevail®	6	1
Standard Plus-Tissue Level®	1	2
Osseospeed®	1	2
Implus TTS®	1	0
Pro-Series®	0	1

**TABLE LEGEND**

*Implant system*

SPI Element®; Thommen Medical AG, Waldenburg, Switzerland  
 Certain® or Prevail®; BIOMET 3i, Palm Beach Gardens, FL, USA  
 Standard Plus-Tissue Level®; Straumann AG, Basel, Switzerland  
 Osseospeed®; AstraTech AB, Molndal, Sweden  
 Implus TTS®; Leader Italia, Cinisello Balsamo, Italy  
 Pro-Series®; Sybron Implant Solutions, Orange, CA, USA

Table 3. Radiographic outcomes of tSFE in NS and S patients. Data are expressed as median,

	non-smokers (NS)	smokers (S)	p (mann-Whitney)
n	25	20*	
post-surgery aGH (mm)	2.3 (IR: 1.3-2.8, range: 0-6.3)	2.5 (IR: 1.7-3.4, range: 0-4.4)	0.675
6-month aGH (mm)	2.0 (IR: 1.2-3.0, range: 0-5.0)	2.4 (IR: 1.6-2.9, range: 0-3.9)	0.707
p (Wilcoxon)	0.211	0.293	
post-surgery SL (mm)	6.5 (IR: 5.7-7.7, range: 4.0-9.5)	6.9 (IR: 6.0-7.7, range: 3.6-8.9)	0.883
6-month SL (mm)	6.7 (IR: 5.7-7.2, range: 3.5-9.4)	6.1 (IR: 5.9-7.4, range: 3.6-9.3)	1
p (Wilcoxon)	0.244	0.244	

**TABLE LEGEND**

\* one implant failed to osseointegrate before the 6-month visit. For this patient, radiographic measurements were not performed at 6 months.

**Discussion**

The *Smart Lift* procedure resulted in a considerable vertical bone enhancement at 6 months in both NS and S groups. The magnitude of these results paralleled previous data on the same technique (Trombelli et al. 2010b, 2012), however, a wide variability in tSFE outcomes is reported among studies. The comparison between treatment outcomes obtained following different tSFE procedures is hindered by differences in the method for assessing the extent of sinus lift. While some studies did not report explicitly the reference points (Horowitz et al. 1997, Zitzmann et al. 1998, Nkenke et al. 2002, Artzi et al. 2003, Toffler 2004, Sotirakis et al. 2005, Calvo-Guirado et al. 2006, Kang 2008, Schmidlin et al. 2008), other studies identified

the “extent of sinus lift” or “bone gain” with the length of the implant portion protruding into the sinus (Winter et al. 2002, Li et al. 2005, Fermergård & Astrand 2008). In contrast, in the present as well as in previous studies (Barone et al. 2008, Pjetursson et al. 2009, Trombelli et al. 2010b, 2012) the extent of sinus lift derived from the linear measurement of the protruding implant and the amount of graft biomaterial apical to the implant apex. The use of aGH as the primary outcome variable is based on long-term radiographic observations which suggest that the presence of graft biomaterial over the implant apex may lead to new bone formation and subsequent apical displacement of the sinus floor (Bragger et al. 2004, Pjetursson et al. 2009). In our study, 6-month aGH and SL were not associated with smoking status, thus suggesting that smoking has a limited impact on the radiographic outcomes of tSFE performed with the *Smart Lift* technique. Limited data are presently available to corroborate our findings. A study where tSFE was performed by osteotomes reported similar bone gain in smoker and non-smoker patients at 6 months following surgery (Leblebicioglu et al. 2005).

Differently, when the effect of smoking was investigated for sinus floor elevations obtained with a lateral approach, current smoking significantly reduced the chance to achieve the mean sinus lift at 9 months following surgery (Anduze-Acher et al. 2012). It may be hypothesized that the detrimental effect of smoking on sinus lift procedures may be in function of the extent of vertical bone enhancement that has to be achieved for implant placement. Also, the effect of smoking may be related to the level of invasiveness of the procedure, which is more limited in the tSFE with *Smart Lift* technique (Trombelli et al. 2010a) compared to the lateral approach (Pjetursson et al. 2008). Also, it must be considered that S patients ranged from light smokers (6 cigarettes/day) to heavy smokers (40 cigarettes/day), thus raising the hypothesis that the inclusion of light smokers may have partly masked the negative effect of smoking on tSFE outcomes. Within their limits, however, the present data seem to exclude a dose-dependent detrimental effect of smoking on the radiographic outcomes of the tSFE procedure.

In our material, limited, non-statistically significant changes of the outcome parameters were observed from presurgery to 6 months in both S and NS patients. To the best of our knowledge, no previous studies investigated the effect of smoking on post-surgery graft remodeling following tSFE procedures. Consistently with our findings, however, a limited extent of graft remodeling was reported at 6-12 months following tSFE by means of osteotomes and adjunctive use of a graft biomaterial in cohorts of patients including smokers and non-smokers (Pjetursson et al. 2009, Kim et al. 2011). Overall, these data seem to confirm that a limited postsurgical loss in graft height occurs during the first months when tSFE is performed with the adjunctive use of graft biomaterials, smoking status being not an influencing factor on the extent of this remodeling.

One implant in the S group failed to osseointegrate before functional loading. The overall early implant failure rate amounted to 2.2% (1 over 45 patients). This data is consistent with a previous systematic review which reported an incidence of early implant failures of 1.3% (55 over 4388 implants) at sites undergone tSFE (Tan et al. 2008). Although the available evidence does not identify smoking as an absolute contraindication for implant placement (Levin et al. 2004, Levin & Schwartz-Arad 2005), recent reviews indicated that smoking affects early implant failure (Palma-Carrió et al. 2011) as well as late implant survival (Klokkevold & Han 2007, Heitz-Mayfield & Huynh-Ba 2009). In particular, the odds ratio for implant failure in the posterior maxilla for smokers vs non-smokers was 6.4 (Huynh-Ba et al. 2008). Also, smoking adversely impacted implant survival at sites undergone sinus floor elevation procedures with a lateral approach (Geurs et al. 2001). Whether and to what extent smoking may affect the long-term survival of implants placed following sinus floor elevation procedures, in general, and tSFE, in particular, needs to be thoroughly investigated.

In our study population, the incidence of membrane perforation was 6.7% (3 over 45 patients), with no significant difference in the incidence of perforations between NS and S patients.



Similarly, a study where tSFE was performed with osteotomes in both smoker and non-smoker patients reported an overall incidence of membrane perforation of 3.7%, however, the Authors did not specify the incidence of perforations within each patient group (Leblebicioglu et al. 2005). The observed incidence of membrane perforation may be considered limited with respect to data on complications following tSFE procedures stemming from a recent systematic review (Tan et al. 2008), and in consideration of the amount of sinus lift achieved. Previous studies on tSFE with osteotomes, in fact, have shown that the incidence of membrane perforation is associated with the extent of sinus lift (Reiser et al. 2001). Interestingly, in our material a substantial SL was obtained immediately after surgery, exceeding 5 mm in 40 out of 45 sinus lift procedures (data not shown). Low incidence of membrane perforation observed in our study could be partly due to the use of adjustable stop devices that restrict the working action of burs and osteotomes to the native bone, thereby preventing the accidental penetration into the sinus cavity. Moreover, the combined use of a trephine bur in close proximity to the sinus floor limited the need for repeated malleting, resulting less traumatic compared to conventional osteotome procedures (Trombelli et al. 2010b, 2012). Our findings, therefore, seem to indicate that the Smart Lift procedure is associated with a limited incidence of complications in both NS and S patients.

In the present study, different implant systems and graft biomaterials were used in association with the *Smart Lift* technique. It may be hypothesized that such technical aspects may to some extent have influenced the observed results, and their distribution within study groups may have exerted a confounding effect on the comparison between NS and S patients. Previous studies, however, did not find any significant effect of implant system, length and diameter on radiographic outcomes following tSFE over a 2-year period (Kim et al. 2011). Differently, a significant influence of the type of graft biomaterial on the extent of post-surgical graft remodeling following tSFE was demonstrated in previous studies (Pjetursson et al. 2009, Kim et al. 2011, Trombelli et al. 2012). Thus, although similar increments in height were obtained in NS and S groups as assessed immediately after surgery, it is possible to admit that the physico-chemical characteristics of graft biomaterials in terms of resorption rate and osteoconductive properties may have partly affected the 6-month outcomes of the tSFE procedure in NS and S groups.

Within their limitations, the results of the present study indicate that tSFE performed with the *Smart Lift* technique results in a substantial vertical augmentation at 6 months post-surgery along with a limited incidence of complications in both smokers and non-smokers.

### **ACKNOWLEDGEMENTS**

*This study was supported by the Research Centre for the Study of Periodontal and Peri-Implant Diseases, University of Ferrara, Italy. The Authors declare that they have no conflict of interest.*

### **References**

- Anduze-Acher, G., Brochery, B., Felizardo, R., Valentini, P., Katsahian, S. & Bouchard, P. (2012) Change in sinus membrane dimension following sinus floor elevation: a retrospective cohort study. *Clinical Oral Implants Research* (epub ahead of print)
- Artzi, Z., Parson, A. & Nemcovsky, C.E. (2003) Wide-diameter implant placement and internal sinus membrane elevation in the immediate postextraction phase: clinical and radiographic observations in 12 consecutive molar sites. *International Journal of Oral and Maxillofacial Implants* **18**: 242-249.
- Barone, A., Santini, S., Sbordone, L., Crespi, R. & Covani, U. (2006) A clinical study of the outcomes and complications associated with maxillary sinus augmentation. *International Journal of Oral and Maxillofacial Implants* **21**: 81-85.
- Barone, A., Cornelini, R., Ciaglia, R. & Covani, U. (2008) Implant placement in fresh extraction sockets and simultaneous osteotome sinus floor elevation: a case series. *International Journal of Periodontics and Restorative Dentistry* **28**: 283-289.
- Bragger, U., Gerber, C., Joss, A., Haenni, S., Meier, A., Hashorva, E. & Lang N.P. (2004) Patterns of tissue remodeling after placement of ITI dental implants using an osteotome technique: a longitudinal radiographic case cohort study. *Clinical Oral Implants Research* **15**: 158-166.



- Calvo-Guirado, J.L., Saez-Yuguero, R. & Pardo-Zamora, G. (2006) Compressive osteotomes for expansion and maxilla sinus floor lifting. *Medicina Oral, Patología Oral y Cirugía Bucal* **11**: E52-55.
- Eufinger, H., König, S. & Eufinger, A. (1997) The role of alveolar ridge width in dental implantology. *Clinical Oral Investigations* **1**: 169-177.
- Eufinger, H., König, S., Eufinger, A. & Machtens, E. (1999) [Significance of the height and width of the alveolar ridge in implantology in the edentulous maxilla. Analysis of 95 cadaver jaws and 24 consecutive patients]. *Mund-, Kiefer- und Gesichtschirurgie* **3 Suppl 1**: S14-8.
- Farina, R., Pramstraller, M., Franceschetti, G., Pramstraller, C. & Trombelli, L. (2011) Alveolar ridge dimensions in maxillary posterior sextants: a retrospective comparative study of dentate and edentulous sites using computerized tomography data. *Clinical Oral Implants Research* **22**: 1138-1144.
- Fugazzotto, P.A. & De Paoli S. (2002) Sinus floor augmentation at the time of maxillary molar extraction: success and failure rates of 137 implants in function for up to 3 years. *Journal of Periodontology* **73**: 39-44.
- Geurs, N.C., Wang, I.C., Shulman, L.B. & Jeffcoat, M.K. (2001) Retrospective radiographic analysis of sinus graft and implant placement procedures from the Academy of Osseointegration Consensus Conference on Sinus Grafts. *International Journal of Periodontics and Restorative Dentistry* **21**: 517-523.
- Heitz-Mayfield, L.J. & Huynh-Ba, G. (2009) History of treated periodontitis and smoking as risks for implant therapy. *International Journal of Oral and Maxillofacial Implants* **24 Suppl**: 39-68.
- Horowitz, R.A. (1997) The use of osteotomes for sinus augmentation at the time of implant placement. *Compendium of Continuing Education in Dentistry* **18**: 441-447, 50-52; quiz 54.
- Huynh-Ba, G., Friedberg, J.R., Vogiatzi, D. & Ioannidou, E. (2008) Implant failure predictors in the posterior maxilla: a retrospective study of 273 consecutive implants. *Journal of Periodontology* **79**: 2256-2261.
- Jones, J.K. & Triplett, R.G. (1992) The relationship of cigarette smoking to impaired intraoral wound healing: a review of evidence and implications for patient care. *Journal of Oral and Maxillofacial Surgery* **50**: 237-239; discussion 239-40.
- Kang, T. (2008) Sinus elevation using a staged osteotome technique for site development prior to implant placement in sites with less than 5 mm of native bone: a case report. *International Journal of Periodontics and Restorative Dentistry* **28**: 73-81.
- Kim, S.M., Park, J.W., Suh, J.Y. & Sohn, D.S. & Lee, J.M. (2011) Bone-added osteotome technique versus lateral approach for sinus floor elevation: a comparative radiographic study. *Implant Dentistry* **20**: 465-470.
- Klokkevold, P.R. & Han, T.J. (2007) How do smoking, diabetes, and periodontitis affect outcomes of implant treatment? *International Journal of Oral Maxillofacial Implants* **22 Suppl**: 173-202. Erratum in: *International Journal of Oral Maxillofacial Implants* **23**: 56.
- Leblebicioglu, B., Ersanli, S., Karabuda, C., Tosun, T. & Gokdeniz, H. (2005) Radiographic evaluation of dental implants placed using an osteotome technique. *Journal of Periodontology* **76**: 385-390.
- Levin, L., Herzberg, R., Dolev, E. & Schwartz-Arad, D. (2004) Smoking and complications of onlay bone grafts and sinus lift operations. *International Journal of Oral Maxillofacial Implants* **19**: 369-373.
- Levin, L. & Schwartz-Arad, D. (2005) The effect of cigarette smoking on dental implants and related surgery. *Implant Dentistry* **14**: 357-361.
- Li, T.F. Sinus floor elevation: a revised osteotome technique and its biological concept. (2005) *Compendium of Continuing Education in Dentistry* **26**: 619-20, 22, 24-6 passim; quiz 30, 69.
- Lin, T.H., Chen, L., Cha, J., Jeffcoat, M., Kao, D.W., Nevins, M. & Fiorellini, J.P. (2012) The effect of cigarette smoking and native bone height on dental implants placed immediately in sinuses grafted by hydraulic condensation. *International Journal of Periodontics and Restorative Dentistry* **32**: 255-261.
- Lindfors, L.T., Tervonen, E.A., Sándor, G.K. & Ylikontiola, L.P. (2010) Guided bone regeneration using a titanium-reinforced ePTFE membrane and particulate autogenous bone: the effect of smoking and membrane exposure. *Oral Surgery, Oral Medicine, Oral Pathology, Oral Radiology and Endodontics* **109**: 825-830.
- Listl, S. & Faggion, C.M. Jr. (2010) An economic evaluation of different sinus lift techniques. *Journal of Clinical Periodontology* **37**: 777-787.
- Mosely, L.H., Finseth, F. & Goody, M. (1978) Nicotine and its effect on wound healing. *Plastic and Reconstructive Surgery* **61**: 570-575.
- Nkenke, E., Schlegel, A., Schultze-Mosgau, S., Neukam, F.W. & Wiltfang, J. (2002) The endoscopically controlled osteotome sinus floor elevation: a preliminary prospective study. *International Journal of Oral and Maxillofacial Implants* **17**: 557-566.
- Palma-Carrió, C., Maestre-Ferrín, L., Peñarrocha-Oltra, D., Peñarrocha-Diago, M.A. & Peñarrocha-Diago, M. (2011) Risk factors associated with early failure of dental implants. A literature review. *Medicina Oral, Patología Oral y Cirugía Bucal* **16**: e514-517.
- Pjetursson, B.E., Tan, W.C., Zwahlen, M. & Lang, N.P. (2008) A systematic review of the success of sinus floor elevation and survival of implants inserted in combination with sinus floor elevation. Part I: Lateral approach. *Journal of Clinical Periodontology* **35 (Suppl. 8)**: 216-240.



- Pjetursson, B.E., Ignjatovic, D., Matuliene, G., Bragger, U., Schmidlin, K. & Lang, N.P. (2009) Transalveolar maxillary sinus floor elevation using osteotomes with or without grafting material. Part II: Radiographic tissue remodeling. *Clinical Oral Implants Research* **20**: 677-683.
- Pramstraller, M., Farina, R., Franceschetti, G., Pramstraller, C. & Trombelli, L. (2011) Ridge dimensions of the edentulous posterior maxilla: a retrospective analysis of a cohort of 127 patients using computerized tomography data. *Clinical Oral Implants Research* **22**: 54-61.
- Reiser, G.M., Rabinovitz, Z., Bruno, J., Damoulis, P.D. & Griffin, T.J. (2001) Evaluation of maxillary sinus membrane response following elevation with the crestal osteotome technique in human cadavers. *International Journal of Oral and Maxillofacial Implants* **16**: 833-840.
- Schmidlin, P.R., Muller, J., Bindl, A. & Imfeld, H. (2008) Sinus floor elevation using an osteotome technique without grafting materials or membranes. *International Journal of Periodontics and Restorative Dentistry* **28**: 401-409.
- Sotirakis, E.G. & Gonshor, A. (2005) Elevation of the maxillary sinus floor with hydraulic pressure. *Journal of Oral Implantology* **31**: 197-204.
- Strietzel, F.P., Reichart, P.A., Kale, A., Kulkarni, M., Wegner, B. & Kuchler, I. (2007) Smoking interferes with the prognosis of dental implant treatment: a systematic review and meta-analysis. *Journal of Clinical Periodontology* **34**: 523-544.
- Tan, W.C., Lang, N.P., Zwahlen, M. & Pjetursson, B.E. (2008) A systematic review of the success of sinus floor elevation and survival of implants inserted in combination with sinus floor elevation. Part II: transalveolar technique. *Journal of Clinical Periodontology* **35(8 Suppl)**: 241-254.
- Toffler, M. (2004) Osteotome-mediated sinus floor elevation: a clinical report. *International Journal of Oral and Maxillofacial Implants* **19**: 266-273.
- Trombelli, L., Minenna, P., Franceschetti, G., Farina, R. & Minenna, L. (2008) SMART-LIFT: una nuova procedura minimamente invasiva per la elevazione del pavimento del seno mascellare. *Dental Cadmos* **76**: 71-83. (article in italian)
- Trombelli, L., Minenna, P., Franceschetti, G., Minenna, L. & Farina, R. (2010a) Transcrestal sinus floor elevation with a minimally invasive technique. *Journal of Periodontology* **81**: 158-166.
- Trombelli, L., Minenna, P., Franceschetti, G., Minenna, L., Iтро, A. & Farina, R. (2010b) Minimally invasive technique for transcrestal sinus floor elevation: a case report. *Quintessence International* **41**: 363-369.
- Trombelli, L., Franceschetti, G., Rizzi, A., Minenna, P., Minenna, L. & Farina, R. (2012) Minimally invasive transcrestal sinus floor elevation with graft biomaterials. A randomized clinical trial. *Clinical Oral Implants Research* **23**: 424-432.
- Winter, A.A., Pollack, A.S. & Odrich, R.B. (2002) Placement of implants in the severely atrophic posterior maxilla using localized management of the sinus floor: a preliminary study. *International Journal of Oral and Maxillofacial Implants* **17**: 687-695.
- Zitzmann, N.U. & Schärer, P. (1998) Sinus elevation procedures in the resorbed posterior maxilla. Comparison of the crestal and lateral approaches. *Oral Surgery, Oral Medicine, Oral Pathology, Oral Radiology and Endodontics* **85**: 8-17.

*Corresponding Author:*

Prof Leonardo Trombelli

Research Center for the Study of Periodontal and Peri-Implant Diseases

University of Ferrara, Italy

E-mail: leonardo.trombelli@unife.it